

Abstract—Testis histological structure was studied in bluefin tuna (*Thunnus thynnus*) from the eastern Atlantic and Mediterranean during the reproductive season (from late April to early June). Testicular maturation was investigated by comparing samples from bluefin tuna caught on their eastward reproductive migration off Barbate (Strait of Gibraltar area) with samples of bluefin tuna fished in spawning grounds around the Balearic Islands. Histological evaluations of cross sections showed that the testis consists of two structurally different regions, an outer proliferative region where germ cells develop synchronously in cysts, and a central region made up of a well-developed system of ducts that convey the spermatozoa produced in the proliferative region to the main sperm duct. Ultrastructural features of the different stages of the male germ cell line are very similar to those described in other teleost species. The bluefin tuna testis is of the unrestricted spermatogonial testicular type, where primary spermatogonia are present all along the germinative portion of the lobules. All stages of spermatogenesis were present in the gonad tissue of migrant and spawning bluefin tuna, although spermatids were more abundant in spawning fish. The testis size was found to increase by a factor of four (on average) during migration to the Mediterranean spawning grounds, whereas the fat bodies (mesenteric lipid stores associated with the gonads) became reduced to half their weight, and the liver mass did not change significantly with sexual maturation. Linear regression analysis of the pooled data of migrant and spawning bluefin tuna revealed a significant negative correlation between the gonad index (I_G) and the fat tissue index (I_F), and a weaker positive correlation between the gonad index (I_G) and the liver index (I_L). Our analyses indicate that the liver does not play a significant role in the storage of lipids and that mesenteric lipid reserves constitute an important energy source for gametogenesis in bluefin tuna.

Manuscript submitted 27 April 2003
to Scientific Editor's Office.

Manuscript approved for publication
25 March 2004 by the Scientific Editor.
Fish. Bull. 102:407–417 (2004).

Testicular development in migrant and spawning bluefin tuna (*Thunnus thynnus* (L.)) from the eastern Atlantic and Mediterranean

Francisco J. Abascal

César Megina

Antonio Medina

Departamento de Biología
Facultad de Ciencias del Mar y Ambientales
Universidad de Cádiz
Av. República Saharaui
11510 Puerto Real
Cádiz, Spain
E-mail address (for A. Medina, contact author): antonio.medina@uca.es

The Atlantic northern bluefin tuna (*Thunnus thynnus thynnus* (L.)), is one of the most commercially valuable wild animals in the world. In the last two decades this species has been subject to intense over-fishing, which has caused a decline in both the eastern and western populations because of lowered recruitment (Mather et al., 1995; Sissenwine et al., 1998). The bluefin tunas (*T. thynnus* and *T. maccoyii*) are unique among tuna species in that they live mainly in cold waters and move into warmer waters to spawn (Olson, 1980; Lee, 1998; Schaefer, 2001); therefore the migratory pattern of these species depends substantially on reproduction. The eastern stock of Atlantic bluefin tuna spawns from June through August in the Mediterranean Sea, where natural conditions are apparently optimal for the survival of offspring. From late April to mid June, bluefin tuna breeding stocks migrate from the North Atlantic to spawning grounds in the Mediterranean (Mather et al., 1995; Ravier and Fromentin, 2001). A good understanding of the reproductive parameters (especially sexual maturation, fecundity, and spawning) of tunas is of paramount importance for population dynamics studies and the management of fisheries that target tunas. Nevertheless, “a very limited amount of scientifically useful infor-

mation is available on the reproductive biology for most tunas” (Schaefer, 2001). Recent work has increased our knowledge on the reproductive biology of female *Thunnus thynnus* in the eastern Atlantic and the Mediterranean (Susca et al., 2000, 2001a, 2001b; Hattour and Macías, 2002; Medina et al., 2002; Mourente et al., 2002), but many questions remain still to be answered regarding male reproductive activity in this and other tuna species.

Histological examination of gonads is a useful tool for assessing the maturity state of fish. However, very few light-microscopy studies have been published on bluefin tuna and no ultrastructural studies of reproductive organs are yet available. The male reproductive cycle of *T. thynnus* has been characterized histologically by Santamaria et al. (2003), and Ratty et al. (1990) and Schaefer (1996, 1998) have reported valuable histological descriptions on male and female gonads of the Pacific albacore (*Thunnus alalunga*) and the yellowfin tuna (*Thunnus albacares*), respectively. In this article we report biometric and histological data on male *T. thynnus* caught during their reproductive migration and spawning period in order to provide further information on the biological aspects of reproduction for this species.

Materials and methods

Samples and condition indices

During the eastward migration, 62 adult male bluefin tuna weighing between 71 and 273 kg (mean 195.17 kg) were obtained from the trap fishery in the area of the Strait of Gibraltar (Barbate, Cádiz, southwestern Spain) from late April to early June 1999, 2000, and 2001. Thirty-four mature males, weighing between 19 and 349 kg (mean 115.11 kg), were sampled in June–July 1999–2001 from the purse-seine fleet operating in the Mediterranean spawning grounds of bluefin tuna off the Balearic Islands. Whenever possible, the total body weight (W) was recorded to the nearest kg. When individual body weights were not available, W was estimated from the fork length (L_F) measurements (recorded to the nearest cm), according to the formula: $W = 0.000019 \times L_F^3$ (Table VIII in Rodríguez-Roda, 1964). Following dissection, the liver, testes, and the fat bodies associated with the gonads were removed and weighed to the nearest g. The condition of the fish was assessed by three different indices. The gonad index (gonadosomatic index) (I_G) is indicative of the maturation state and was calculated as: $I_G = (W_G / W) \times 100$, where W_G = gonad weight. The liver index (hepatosomatic index) (I_L) and fat-body index (I_F) were calculated as $I_L = (W_L / W) \times 100$, and $I_F = (W_F / W) \times 100$ (where W_L and W_F represent liver and fat-body weights), respectively, and are considered as good indicators of the metabolic condition and energy reserves of the fish. All measurements are expressed as means \pm SD.

Histology

For light microscopy, tissue samples from the central part of the testes were fixed for 48–96 hours in 10% formalin in phosphate buffer, 0.1 M, pH 7.2. After dehydration in ascending concentrations of ethanol, a part of each sample was embedded in paraffin wax and the remainder was embedded in plastic medium (2-hydroxyethyl-methacrylate). Paraffin sections (6 μ m thick) were stained with haematoxylin-eosin, and plastic sections (3 μ m thick) were stained with toluidine blue. These were examined and photographed on a Leitz DMR BE light microscope.

For electron microscopy, small fragments of testis were fixed for 3–4 hours in 2.5% glutaraldehyde buffered with 0.1 M sodium cacodylate buffer (pH 7.2). Following two 30-min washes in cacodylate buffer, they were postfixed for 1 hour at 4°C in cacodylate-buffered 1% osmium tetroxide, rinsed several times in buffer, dehydrated in ascending concentrations of acetone, and embedded in epoxy resin (either Epon 812 or Spurr). Thin sections (~80 nm thick) were picked up on copper grids, stained with uranyl acetate and lead citrate, and examined in a Jeol 1200 EX transmission electron microscope. Approximate dimensions provided for germ cells are measurements (means \pm SD) of the largest cell diameters on electron micrographs.

Statistical analysis

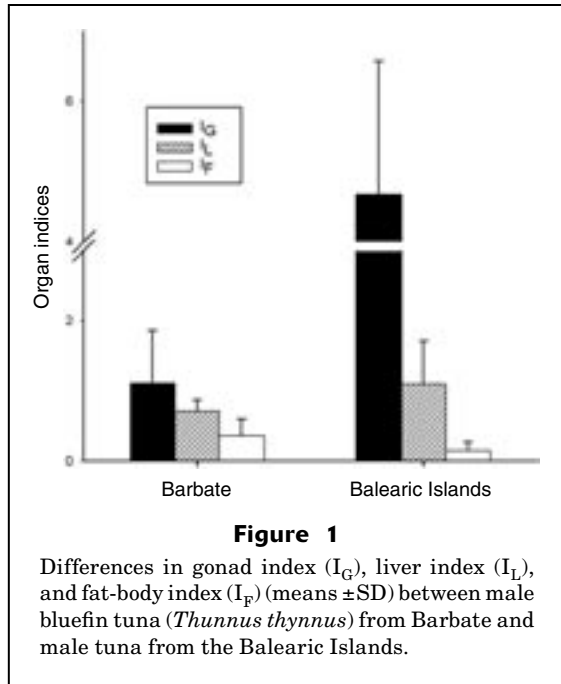
The bluefin tuna specimens used in this study showed considerable variability in size, especially those caught by purse seine in Balearic waters, where weight ranged between 12 and 349 kg. The purse-seine fishery is, in fact, much less size-selective than are traps, which seldom catch small bluefin tuna (Rodríguez-Roda, 1964; Mather et al., 1995). Analysis of covariance (ANCOVA), with body weight as covariate, was used as the most suitable method (García-Berthou, 2001) to test interannual differences in the weight of the organs within the two sampling sites. ANCOVA was likewise applied to compare the weights of the three organs between both areas. All data were previously log-transformed to meet the prerequisites of normality and homoscedasticity (Zar, 1996). Linear least-squares regression analyses were performed to test possible correlations between I_G and the two other indices (I_L and I_F) by using the pooled data of Barbate and the Balearic Islands. In the regression between I_G and I_F , the Balearic samples corresponding to year 2001 were excluded because the reduced fat-body size (adipose tissue was almost non-existent in the mesentery) of these small bluefin tuna did not permit an accurate weight measurements on board. The values of the indices were arcsine-transformed prior to the statistical analysis (Zar, 1996). A P -value ≤ 0.05 was considered statistically significant for all tests.

Results

Condition indices

ANCOVA did not reveal significant interannual differences in gonad, liver, and fat-body weight in the samples of Barbate as well as in those of the Balearic Islands. In contrast, a strongly significant difference in testicular size ($P < 0.0001$) was found in comparing data of maturing bluefin tuna from Barbate (migrant tuna) with fully mature fish from the Balearic Islands (spawning fish). In fact, as shown in Figure 1, the average I_G was more than fourfold higher in the Balearic Islands than it was in Barbate (4.81 ± 1.77 vs. 1.12 ± 0.57). This finding may indicate a noticeable increase in sperm production during reproductive migration to the Mediterranean spawning grounds. Significant differences between maturing and spawning tuna were also found in fat-body weight, the volume of which dropped to about half by spawning time. Thus, I_F fell from 0.36 ± 0.24 in migrating fish to 0.16 ± 0.12 in spawning fish (see Fig. 1). The liver mass, however, did not differ significantly ($P = 0.31$) between the two samples.

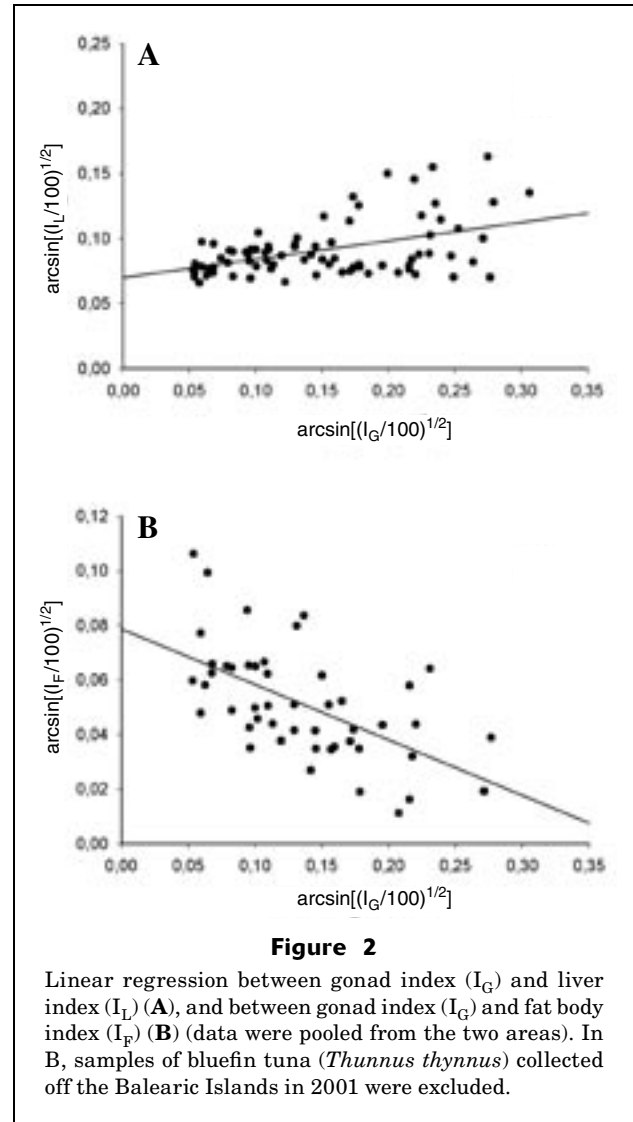
Figure 2 illustrates linear regression analysis between I_G and I_L , and between I_G and I_F . A significant negative correlation ($r^2 = 0.34$; $P < 0.0001$) was found between I_G and I_F , indicating that the amount of mesenteric fat tissue decreases as the gonad matures. In contrast, there was a positive, though somewhat weak, correlation



($r^2=0.21$; $P<0.0001$) between I_G and I_L , which suggests a slight growth of the liver with sexual maturation.

Histology

The testes of *Thunnus thynnus* are paired, elongate organs that appear attached to the dorsal body wall by a mesentery. The fat body, which is closely associated with the gonad, consists of a variable amount of adipose tissue. The testis is composed of a dense array of lobules converging on the main sperm duct (vas deferens) and terminating blindly beneath the tunica albuginea at the periphery (Fig. 3, A and B). Two distinct zones can be distinguished in cross sections of the testes (Fig. 3A). At the outer region, the seminiferous lobules have a thick wall formed by the germinal epithelium, where germ cells develop in association with Sertoli cells; the lumina of the lobules are filled with spermatozoa that have been released after completion of the spermiogenetic process (Fig. 3, B and C). As a result of the release of mature sperm from spermatocysts into the lobule lumina, the germinal epithelium becomes discontinuous (Fig. 3B). The transition from the outer to the central region of the testis is marked by an abrupt change in the configuration of the testicular lobules, which lose the germinal epithelium and become ducts where lobule function has shifted from sperm production to sperm storage (Fig. 3C). Thus, the only sex cells that are found in the central part of the testis are mature spermatozoa, which fill the swollen lumina of the lobules. In this zone the testis ducts constitute an intricate network of channels that convey the spermatozoa produced in the proliferative region to the main sperm duct (Fig. 3, A and D), which is thick walled and located in the center of the testis (Fig. 3D).



The gametes develop in groups of isogenic cells called germinal cysts or spermatocysts, where the process of differentiation is synchronous (Fig. 4). Primary spermatogonia are large, single cells (Fig. 4A) that are distributed all along the germinal epithelium, as is characteristic of the teleost unrestricted testicular type. Spermatogonia B resulting from successive mitoses of spermatogonia A are found in small groups, whereas spermatocytes and spermatids are grouped within larger spermatocysts (Figs. 3, B and C, 4). The cysts containing late spermatids and spermatozoa, prior to spermiation, display a particular alveolar appearance due to the orientation of the spermatid heads facing the lobule walls and the bundles of flagella directed toward the seminiferous lobule lumen (Fig. 4, A, C, and D).

Active spermatogenesis was observed to occur both in migrant bluefin tuna from the Strait of Gibraltar (Fig. 4, A and B) and spawning fish from the Mediterranean (Fig. 4, C and D). In both cases, all stages of the male

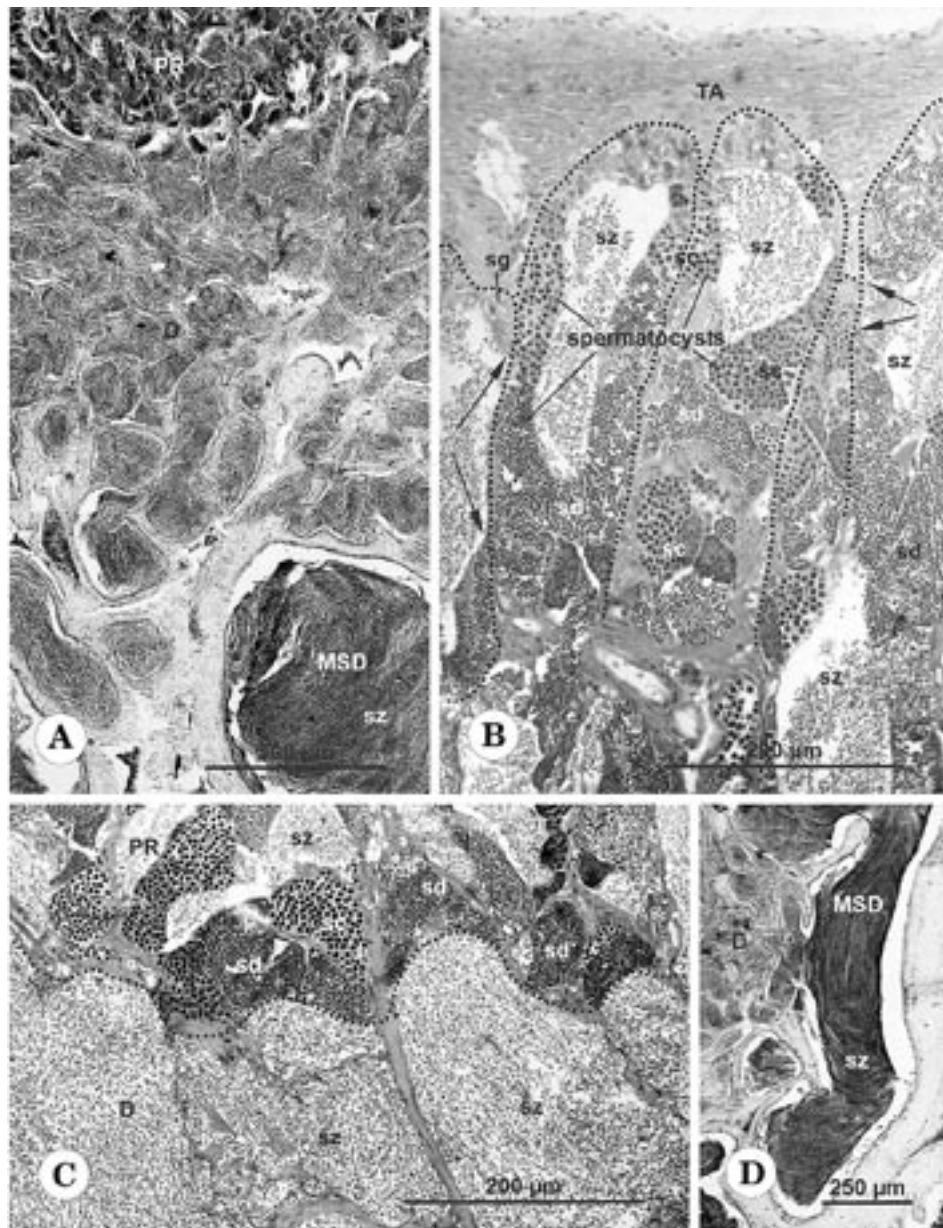


Figure 3

Light micrographs depicting the histological organization of the bluefin tuna (*Thunnus thynnus*) testis. (A) Transverse section showing the outer proliferative region (PR) of the testis and the inner region, which includes the testis duct system (D) and the main sperm duct (MSD). (B) Peripheral zone of the testis where the distal ends of some tubules (dotted lines) terminate beneath the tunica albuginea (TA). (C) Transition (dotted line) between the outer region (PR) of the testis, where the lobules contain developing germinal cysts, and the inner region (D), whose lobule walls enclose only mature spermatozoa. (D) Main sperm duct (MSD) filled with a compact mass of spermatozoa that are incorporated (arrowhead) from the testis ducts (D). Arrows = discontinuities in the germinal epithelium; sc = spermatocytes; sd = spermatids; sg = spermatogonia; sz = spermatozoa. All samples are from Barbate (A and D, paraffin-embedded sections stained with haematoxylin-eosin; B and C, toluidine-blue-stained plastic-embedded sections).

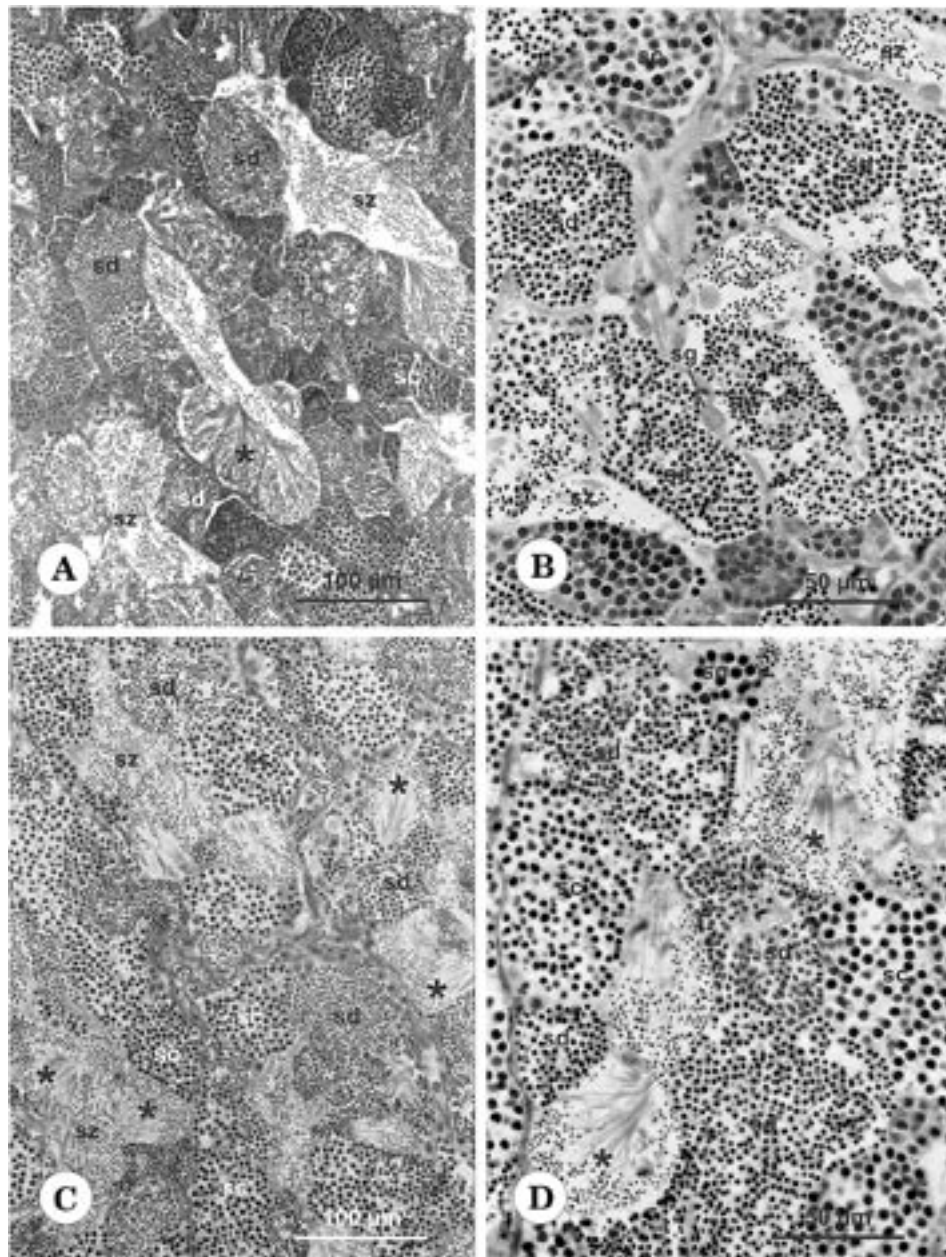
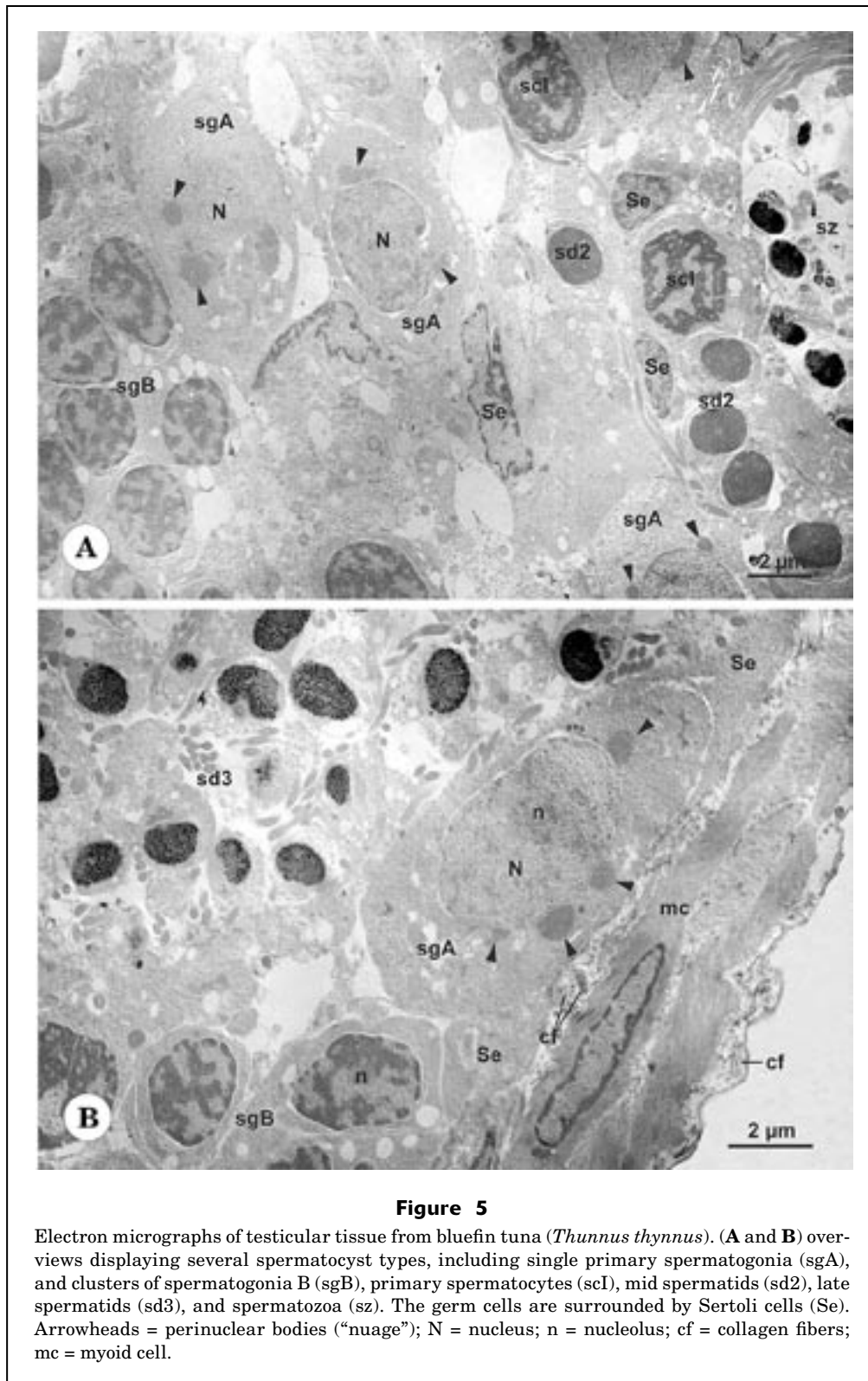


Figure 4

Spermatocysts in the testis proliferative region of bluefin tuna (*Thunnus thynnus*) from Barbate (A and B) and the Balearic Islands (C and D). All stages of spermatogenesis are present in both cases, although spermatid cysts containing late spermatids and spermatozoa (asterisks) are somewhat more abundant in specimens from the Balearic Islands. Arrow = dividing spermatocytes; sc = spermatocytes; sd = spermatids; sg = primary spermatogonium; sz = spermatozoa. Plastic-embedded sections (A–D) were stained with toluidine blue.

germ cell line were present in the gonads. In addition, large amounts of spermatozoa had accumulated in the central system of ducts and in the main sperm duct, both of which appear to function as reservoirs of sperm. In specimens from Barbate, spermatocytes and sper-

matids were abundant (Fig. 4B), whereas in most tuna collected in the Balearic area spermatids predominated over spermatocytes. Cysts containing late spermatids and spermatozoa were particularly common (Fig. 4, C and D).



Ultrastructure

Primary spermatogonia are large, ovoid cells ($8.55 \pm 1.07 \mu\text{m}$) whose nucleus ($>5 \mu\text{m}$ in its largest diameter) shows

diffuse chromatin and a single central nucleolus. The cytoplasm contains free ribosomes, a few mitochondria, endoplasmic reticulum cisternae, and several masses

of electron-dense perinuclear material (“nuages”) that indicate nucleocytoplasmic transport (Fig. 5, A and B). Such chromatoid bodies persist throughout spermatogenesis until the spermatid stage, but their size and number is far higher in primary spermatogonia. Spermatogonia B are grouped in clusters of a few cells. They are perceptibly smaller ($6.75 \pm 0.37 \mu\text{m}$) than spermatogonia A and their nucleus contains patchy chromatin (Fig. 5, A and B).

Spermatocytes form clusters in which the cells are interconnected by cytoplasmic bridges. Primary spermatocytes ($4.84 \pm 0.45 \mu\text{m}$) show a heterochromatic nucleus ($\sim 3.5 \mu\text{m}$ in diameter) that varies in appearance depending on the prophase-I stage. The cytoplasm contains free ribosomes (mostly polysomes), mitochondria, clear vesicles, and the diplosome (Figs. 5A, 6A). Synaptonemal complexes are clearly recognizable at pachytene (Fig. 6A). Secondary spermatocytes are apparently short-lived cells because they are rare in histological samples—a finding that suggests that the second meiotic division is triggered shortly after completion of the first division. Spermatocytes II are difficult to distinguish morphologically from early spermatids, although they are slightly larger ($3.31 \pm 0.47 \mu\text{m}$). The cytoplasm is more reduced than in spermatocytes I and the nucleus shows diffuse chromatin forming moderately electron-dense patches (Fig. 6B).

During spermiogenesis, the spermatid nucleus changes in shape and decreases in volume as the chromatin condenses. In early spermatids ($2.39 \pm 0.28 \mu\text{m}$) the spherical nucleus shows a dense chromatin with some electron-lucent areas (Fig. 6C). Then the chromatin becomes more homogeneous in mid spermatids ($2.56 \pm 0.21 \mu\text{m}$) (Figs. 5A, 6D), and eventually in late spermatids ($1.81 \pm 0.32 \mu\text{m}$) condenses into a coarse granular pattern, whereas the nucleus assumes an ovoid shape and forms a basal indentation over the proximal segment of the axoneme (Fig. 6E). Cytoplasmic changes involve elongation of the flagellum, reduction of the cytoplasmic mass, and coalescence of the mitochondria into a few large spherical units located around the proximal portion of the axoneme. Rotation of the nucleus does not take place during spermiogenesis, therefore the flagellum axis remains parallel to the base of the nucleus and the spermatozoon shows the typical ultrastructure of teleostean type-II sperm (Fig. 6F).

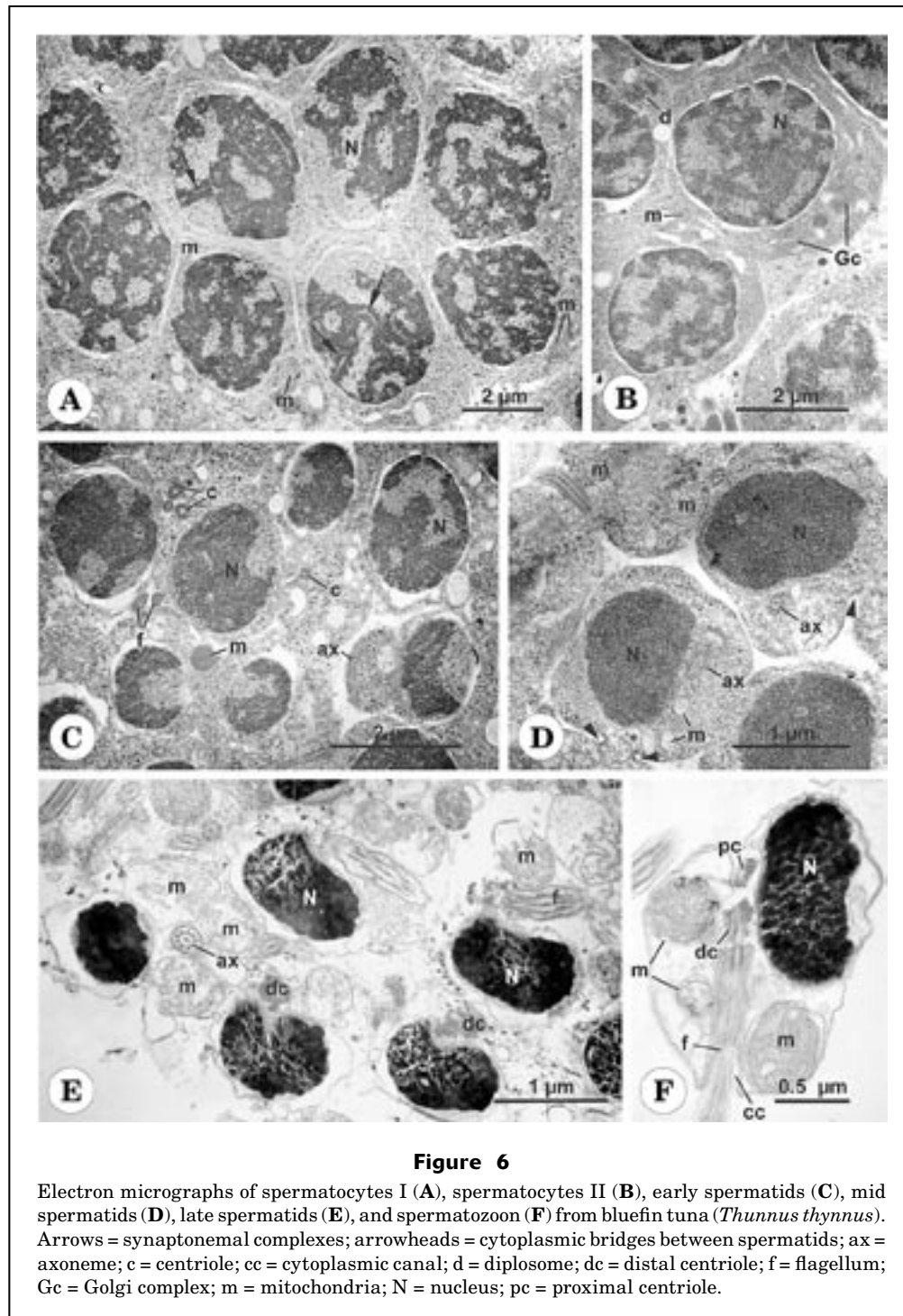
Discussion

Histologically, the bluefin tuna testis is of the unrestricted spermatogonial testicular type found in most teleosts, where spermatogonia occur along the greater part of the testicular tubules. In the restricted spermatogonial testicular type of the atheriniforms, on the other hand, the spermatogonia are confined to the distal end of the tubules, and spermatogenesis proceeds as the germ cells approach the efferent ducts (Grier et al., 1980; Grier, 1981). Efferent ducts are generally absent in unrestricted spermatogonial testes, so that germinal cysts

form along the testicular tubule length (Grier et al., 1980; Grier, 1981; Lahnsteiner et al., 1994). However, in maturing and spawning bluefin tuna a well-developed network of ducts collects the sperm produced by the germinal epithelium and voids them into the main sperm duct. The central ducts of the testis are continuous with the proliferative segment of the testicular lobules, which lose the germinal epithelium in the innermost region of the testis and function as sperm storage structures. This process has been documented in the common snook (*Centropomus undecimalis*) (Grier and Taylor, 1998), the cobia (*Rachycentrum canadum*) (Brown-Peterson et al., 2002), and the swamp eel (*Synbranchus marmoratus*) (Lo Nostro et al., 2003). Grier et al. (1980) showed that in the atheriniform *Fundulus grandis* the efferent duct wall cells derive from Sertoli cells. A system of efferent ducts has been described in other species of teleosts possessing testes of the unrestricted spermatogonial type (Rasotto and Sadovy, 1995; Manni and Rasotto, 1997). As has been shown in other species of the genus (Ratty et al., 1990; Schaefer, 1996; 1998), the main sperm duct of *T. thynnus* has a thick wall and is located near the center of the testis, whereas in many other teleosts the main duct is dorsal (Grier et al., 1980).

Ultrastructural features of bluefin tuna spermatogenesis are comparable to those described extensively in teleosts (for examples of recent literature see Gwo and Gwo, 1993; Stoumboudi and Abraham, 1996; Quagio-Grassiotto et al., 2001; Huang et al., 2002; Koulis et al., 2002; Fishelson, 2003). The primary spermatogonia are the largest male germ cells and exhibit several conspicuous perinuclear (“nuage”) bodies. After several divisions they give rise to cysts of secondary spermatogonia that enter meiosis to produce successively primary and secondary spermatocytes. Primary spermatocytes are abundant, particularly at the pachytene phase, and are therefore thought to be of long duration. In contrast, the spermatocyte-II stage is thought to be the shortest spermatogenetic step, because, as occurs in teleosts in general, it is the least frequent in histological samples. Spermiogenesis develops without the occurrence of rotation of the spermatid nucleus, resulting in a teleostean type-II spermatozoon (Mattei, 1970), in which the flagellar axis lies tangential to the nucleus instead of being inserted perpendicular to its base (Abascal et al., 2002).

Santamaria et al. (2003) divided the testicular cycle of *T. thynnus* caught in Mediterranean waters from February to September into five periods. Those developmental stages are similar to stages 2–6 classified by Grier (1981) for a generalized teleost annual reproductive cycle. Most probably, stage 1 (spermatogonial proliferation) occurs in Mediterranean bluefin tuna between October and January. More recently, annual histological changes in the germinal epithelium have been used to identify five distinct reproductive classes in males of several teleost species (Grier and Taylor, 1998; Taylor et al., 1998; Brown-Peterson et al., 2002; Lo Nostro et al., 2003). It is assumed that the most advanced maturation classes in males are characterized by the presence of a discontinuous germinal epithelium. According to this criterion, all



of the samples examined in the present study correspond to the mid- and late-maturation stages proposed by Grier and Taylor (1998), and Taylor et al. (1998). Testes at these stages become storage organs that are filled with sperm. The present study encompasses only a short period of the reproductive cycle, which comprises final gonad maturation. However, descriptions of the testicular histology throughout the annual cycle (Santamaria

et al., 2003) appear to indicate that different maturation classes might be defined in the bluefin tuna based on histological examination of the germinal epithelium (see Taylor et al., 1998; Brown-Peterson et al., 2002).

Final sexual maturation involves a considerable increase in testis size, but no apparent remarkable histological changes, with the exception of a slightly higher frequency of the most advanced stages of spermatogen-

esis in fully mature bluefin tuna. The different testicular development of maturing and spawning tuna is reflected by their respective average I_G , which was fourfold higher in spawning fish. An equivalent gonad growth was found in the females collected in the same samplings (Medina et al., 2002), indicating a spatiotemporal parallelism in the gonad maturation cycle and a good synchronization of the reproductive peak in the two sexes. The maturation schedule differs between the two sexes, however, in that males are capable of generating mature spermatozoa while still on migration, whereas females do not appear to develop fully mature oocytes until they have reached the spawning grounds (Medina et al., 2002). Therefore, even though mature spermatozoa can be found in testicular ducts during prolonged periods throughout the reproductive cycle, it is unlikely that males are actually capable of spawning out of reproductive season.

The seasonal I_G profile of the bluefin tuna appears to be similar to that of the pelagic, highly migratory perciform *Rachycentron canadum* (Brown-Peterson et al., 2002), and the swamp eel (*Synbranchus marmoratus*) (Lo Nostro et al., 2003), in which peak I_G values occur when the reproductive activity is at a maximum. A different situation has been reported in the common snook (Taylor et al., 1998), where the highest I_G levels correspond with the mid maturation class and decrease during the latter part of the reproductive season. The biological significance of these different I_G profiles in terms of reproductive strategies is yet unknown because a very limited number of species have been examined so far.

Because spermatozoa are by far the most abundant cells in mature testes, the gonad weight becomes a good indicator of the quantity of sperm produced by a fish (Billard, 1986). Therefore, the significant increase in I_G that occurred between samplings off Barbate and the Balearic Islands would indicate that, during migration, bluefin tuna can raise several times the volume of sperm accumulated in the testes. The apparently high spermatogenic activity observed in bluefin tuna caught on the spawning grounds suggests that bluefin tuna have the ability to regenerate testicular sperm stores. Continuous sperm production could be important because external fertilization requires the release of large amounts of sperm to ensure successful fertilization of eggs, especially when egg size is small. In addition, it should be noted that tunas spawn multiple times (June, 1953; Yuen, 1955; Buñag, 1956; Otsu and Uchida, 1959; Baglin, 1982; Stéquert and Ramcharrun, 1995) and can spawn almost daily throughout the reproductive season (Hunter et al., 1986; McPherson, 1991; Schaefer, 1996, 1998, 2001; Farley and Davis, 1998; Medina et al., 2002).

From histological examination of the sperm ducts, and based on the amount of sperm present and the staining of the epithelium, Schaefer (1998) proposed a spawning interval of 1.03 days for spawning male *Thunnus albacares* throughout the eastern Pacific Ocean. The spawning rate estimated for reproductively active females with the postovulatory-follicle method was 1.19

days (Schaefer, 1998), which coincides with the spawning interval estimated for female *T. thynnus* around the Balearic Islands (Medina et al., 2002). Unfortunately, we could not make a reliable estimation of the male spawning interval in our samples. Two possible reasons may account for this failure. One reason is that many of the samples of gonadal tissue did not include the main sperm duct. On the other hand, no clear evidence of spawning was identified by histological examination of those specimens processed that had sperm ducts. A plausible explanation for this fact is that recent sperm release can be detected only within 12 hours after the spawning event (Schaefer, 1996); hence for male spawning to be detected the fish would have to be sampled in a narrow range of times following spawning, which Schaefer (1996) established between 00.01 and 12.00 hours after spawning for *Thunnus albacares*. It would be worth conducting further research on bluefin tuna at their spawning grounds, by attempting to cover a broad range of sampling times in order to ensure collection of specimens shortly after gamete release. In this way, useful information would be obtained on such reproductive parameters as spawning schedules, fecundity, and the energy cost of spawning, which are essential for ecological assessments of the reproductive potential.

It is noteworthy that male tuna, as small as 20 kg in weight (~100 cm L_F), were caught on the spawning grounds in our study. They had gonad indices over 5% and histological features indicative of full maturity. These observations indicate that the eastern stock of Atlantic northern bluefin tuna can reach maturity at age 3 years and thus support conclusions of previous studies (Rodríguez-Roda, 1967; Hattour and Macías, 2002; Susca et al., 2001a, 2001b; Medina et al., 2002); western bluefin tuna, on the other hand, mature at an older age, which has been estimated at 6 years (Baglin, 1982).

Prior to sexual maturation, marine fish generally accumulate large lipid deposits, primarily triacylglycerols, which are subsequently mobilized to support gonad development and spawning migration (Bell, 1998). The major lipid storage sites are the mesenteric tissue, muscle, liver, and subdermal fat layers (Ackman, 1980). In bluefin tuna the liver does not appear to play an important role in lipid storage but is mainly involved in processing fatty acids mobilized from other bodily sources (Mourente et al., 2002). This metabolic pattern is consistent with our observations of weight modifications for liver and fat body from maturation through the spawning period. Although I_L increases only slightly with sexual maturation, I_F undergoes a marked decrease at the time of maximum gonad development. Thus, the regression analysis of the relationship between I_G and I_F shows a significant negative correlation, which reveals a depletion of mesenteric fat stores as the testes grow. The occurrence of a similar situation in females (Medina et al., 2002; Mourente et al., 2002) and in male and female *Thunnus alalunga* (Ratty et al., 1990) has led to the conclusion that fat-body lipid reserves provide an important energy source for gametogenesis in tunas.

Acknowledgments

This study has been funded by the Spanish government and the European Union (projects 1FD1997-0880-C05-04 and Q5RS-2002-01355). The authors wish to thank two anonymous reviewers for helpful recommendations. We also thank Pesquerías de Almadraba, S. J. and Ginés J. Méndez Alcalá (G. Méndez España, S. L.) for co-operation and assistance. The invaluable technical assistance of Agustín Santos and José Luis Rivero is greatly appreciated. G. Mourente lent useful help in our discussion on lipids.

Literature cited

- Abascal, F. J., A. Medina, C. Megina, and A. Calzada.
2002. Ultrastructure of *Thunnus thynnus* and *Euthynnus alletteratus* spermatozoa. *J. Fish Biol.* 60:147–153.
- Ackman, R. G.
1980. Fish lipids, part 1. *In* Advances in fish science and technology (J. J. Connell, ed.), p. 86–103. Fishing News Books Ltd., Farnham, England.
- Baglin, R. E., Jr.
1982. Reproductive biology of western Atlantic bluefin tuna. *Fish. Bull.* 80:121–134.
- Bell, J. C.
1998. Current aspects of lipid nutrition in fish farming. *In* Biology of farmed fish (K. D. Black and A. D. Pickering, eds.), p. 114–145. Sheffield Academic Press Ltd., Sheffield, England.
- Billard, R.
1986. Spermatogenesis and spermatology of some teleost fish species. *Reprod. Nutr. Dévelop.* 26:877–920.
- Brown-Peterson, N. J., H. J. Grier, and R. M. Overstreet.
2002. Annual changes in germinal epithelium determine male reproductive classes of the cobia. *J. Fish Biol.* 60:178–202.
- Buñag, D. M.
1956. Spawning habits of some Philippine tuna based on diameter measurements of the ovarian ova. *Philipp. J. Fish.* 26:877–920.
- Farley, J. H., and T. L. O. Davis.
1998. Reproductive dynamics of southern bluefin tuna, *Thunnus maccoyii*. *Fish. Bull.* 96:223–236.
- Fishelson, L.
2003. Comparison of testes structure, spermatogenesis, and spermatocytogenesis in young, aging, and hybrid cichlid fish (Cichlidae, Teleostei). *J. Morphol.* 256:285–300.
- García-Berthou, E.
2001. On the misuse of residuals in ecology: testing regression residuals vs. the analysis of covariance. *J. Anim. Ecol.* 70:708–711.
- Grier, H. J.
1981. Cellular organization of the testis and spermatogenesis in fishes. *Am. Zool.* 21:345–357.
- Grier, H. J., J. R. Linton, J. F. Leatherland, and V. L. De Vlaming.
1980. Structural evidence for two different testicular types in teleost fishes. *Am. J. Anat.* 159:331–345.
- Grier, H. J., and R. G. Taylor.
1998. Testicular maturation and regression in the common snook. *J. Fish Biol.* 53:521–542.
- Gwo, J.-C., and H.-H. Gwo.
1993. Spermatogenesis in the black porgy, *Acanthopagrus schlegeli* (Teleostei: Perciformes: Sparidae). *Mol. Reprod. Dev.* 36:75–83.
- Hattour, A., and D. Macías.
2002. Bluefin tuna maturity in Tunisian waters: a preliminary approach. *Col. Vol. Sci. Pap. ICCAT* (International Commission for the Conservation of Atlantic Tunas) 54: 545–553.
- Huang, J.-D., M.-F. Lee, and C.-F. Chang.
2002. The morphology of gonadal tissue and male germ cells in the protandrous black porgy, *Acanthopagrus schlegeli*. *Zool. Stud.* 41:216–227.
- Hunter, J. R., B. J. Macewicz, and J. R. Sibert.
1986. The spawning frequency of skipjack tuna, *Katsuwonus pelamis*, from the South Pacific. *Fish. Bull.* 84:895–503.
- June, F. C.
1953. Spawning of yellowfin tuna in Hawaiian waters. *U. S. Fish and Wildlife Service, Fish. Bull.* 54:47–64.
- Koulis, S., C. R. Kramer, and H. J. Grier.
2002. Organization of the male gonad in a protogynous fish (Teleostei: Labridae). *J. Morphol.* 254:292–311.
- Lahnsteiner, F., R. A. Patzner, and T. Weismann.
1994. Testicular main ducts and spermatic ducts in some cyprinid fishes I. Morphology, fine structure and histochemistry. *J. Fish Biol.* 44:937–951.
- Lee, C. L.
1998. A study on the feasibility of the aquaculture of the southern bluefin tuna, *Thunnus maccoyii*, in Australia, 92 p. Agriculture Fisheries and Forestry-Australia (AFFA), Canberra, Western Australia.
- Lo Nostro, F., H. Grier, L. Andreone, and G. A. Guerrero.
2003. Involvement of the gonadal germinal epithelium during sex reversal and seasonal testicular cycling in the protogynous swamp eel, *Synbranchus marmoratus* Bloch 1795 (Teleostei, Synbranchidae). *J. Morphol.* 257:107–126.
- Manni, L., and M. B. Rasotto.
1997. Ultrastructure and histochemistry of the testicular efferent duct system and spermiogenesis in *Opistognathus whitehurstii* (Teleostei, Trachinoidei). *Zoomorphol.* 117:93–102.
- Mather, F. J., III, J. M. Mason, and A. C. Jones.
1995. Historical document: life history and fisheries of Atlantic bluefin tuna. NOAA Tech. Memo. NMFS-SEFSC 370, 165 p.
- Mattei, X.
1970. Spermiogenèse comparée des poissons. *In* Comparative spermatology (B. Baccetti, ed.), p. 57–69. Academic Press, New York, NY.
- McPherson, G. R.
1991. Reproductive biology of yellowfin tuna in the eastern Australian fishing zone, with special reference to the north-western Coral Sea. *Austr. J. Mar. Freshw. Res.* 42:465–477.
- Medina, A., F. J. Abascal, C. Megina, and A. García.
2002. Stereological assessment of the reproductive status of female Atlantic northern bluefin tuna, *Thunnus thynnus* (L.), during migration to Mediterranean spawning grounds through the Strait of Gibraltar. *J. Fish Biol.* 60:203–217.
- Mourente, G., C. Megina, and E. Díaz-Salvago.
2002. Lipids in female northern bluefin tuna (*Thunnus thynnus thynnus* L.) during sexual maturation. *Fish. Physiol. Biochem.* 24:351–363.
- Olson, R. J.
1980. Synopsis of biological data on the southern bluefin

- tuna, *Thunnus maccoyii* (Castelnau, 1872) Inter-Am. Trop. Tuna Comm., Spec. Rep. 2:151–212.
- Otsu, T., and R. N. Uchida.
1959. Sexual maturity and spawning of albacore in the Pacific Ocean. U. S. Fish and Wildlife Service, Fish. Bull. 59:287–305.
- Quagio-Grassiotto, I., J. N. C. Negrão, E. D. Carvalho, and F. Foresti.
2001. Ultrastructure of spermatogenic cells and spermatozoa in *Hoplías malabaricus* (Teleostei, Characiformes, Erythrinidae). J. Fish Biol. 59:1494–1502.
- Rasotto, M. B., and Y. Sadovy.
1995. Peculiarities of the male urogenital apparatus of two grunt species (Teleostei, Haemulidae). J. Fish Biol. 46:936–948.
- Ratty, F. J., R. M. Laurs, and R. M. Kelly.
1990. Gonad morphology, histology, and spermatogenesis in south Pacific albacore tuna *Thunnus alalunga* (Scombridae). Fish. Bull. 88:207–216.
- Ravier, C., and J.-M. Fromentin.
2001. Long-term fluctuations in the eastern Atlantic and Mediterranean bluefin tuna population. ICES (International Council for the Exploration of the Sea). J. Mar. Sci. 58:1299–1317.
- Rodríguez-Roda, J.
1964. Biología del atún, *Thunnus thynnus* (L.), de la costa sudatlántica de España. Inv. Pesq. 25:33–146.
- Rodríguez-Roda, J.
1967. Fecundidad del atún, *Thunnus thynnus* (L.), de la costa sudatlántica de España. Inv. Pesq. 31:33–52.
- Santamaria, N., A. Corriero, S. Desantis, D. Zubani, R. Gentile, V. Sciscioli, M. de la Serna, and C. R. Bridges.
2003. Testicular cycle of the Mediterranean bluefin tuna (*Thunnus thynnus* L.). Cah. Opt. Med. 60:183–185.
- Schaefer, K. M.
1996. Spawning time, frequency, and batch fecundity of yellowfin tuna, *Thunnus albacares*, near Clipperton Atoll in the eastern Pacific Ocean. Fish. Bull. 94:98–112.
1998. Reproductive biology of yellowfin tuna (*Thunnus albacares*) in the eastern Pacific Ocean. Inter-Am. Trop. Tuna Comm., Bull. 21:201–272.
2001. Reproductive biology of tunas. In Tuna: physiology, ecology and evolution (B. A. Block and E. D. Stevens, eds.), p. 225–270. Academic Press, London.
- Sissenwine, M. P., P. M. Mace, J. E. Powers, and G. P. Scott.
1998. A commentary on western Atlantic bluefin tuna assessments. Trans. Am. Fish. Soc. 127:838–855.
- Stéquert, B., and B. Ramcharrun.
1995. La fécondité du listao (*Katsuwonus pelamis*) de l'ouest de l'océan Indien. Aquat. Living Resour. 8:79–89.
- Stoumboudi, M. Th., and M. Abraham.
1996. The spermatogenetic process in *Barbus longiceps*, *Capoeta damascina* and their natural sterile hybrid (Teleostei, Cyprinidae). J. Fish Biol. 49:458–468.
- Susca, V., M. Deflorio, A. Corriero, C. R. Bridges, and G. De Metrio.
2000. Sexual maturation in the bluefin tuna (*Thunnus thynnus*) from the central Mediterranean Sea. In Proceedings of the 6th international symposium on the reproductive physiology of fish (B. Noberg, O. S. Kjesbu, G. L. Taranger, E. Andersson, and S. O. Stefansson, eds.), p. 105. Fish Symp. 99. Department of Fisheries and Marine Biology, Univ. Bergen, Bergen, Norway.
- Susca, V., A. Corriero, C. R. Bridges, and G. De Metrio.
2001a. Study of the sexual maturity of female bluefin tuna: purification and characterization of vitellogenin and its use in an enzyme-linked immunosorbent assay. J. Fish Biol. 58:815–831.
- Susca, V., A. Corriero, M. Deflorio, C. R. Bridges, and G. De Metrio.
2001b. New results on the reproductive biology of the bluefin tuna (*Thunnus thynnus*) in the Mediterranean. Col. Vol. Sci. Pap. ICCAT 52:745–751.
- Taylor, R. G., H. J. Grier, and J. A. Whittington.
1998. Spawning rhythms of common snook in Florida. J. Fish Biol. 53:502–520.
- Yuen, H. S. H.
1955. Maturity and fecundity of bigeye tuna in the Pacific. U.S. Fish and Wildlife Service Special Scientific Report: Fisheries 150, 30 p. Washington, D.C.
- Zar, J. H.
1996. Biostatistical analysis, 662 p. Prentice-Hall, Upper Saddle River, NJ.